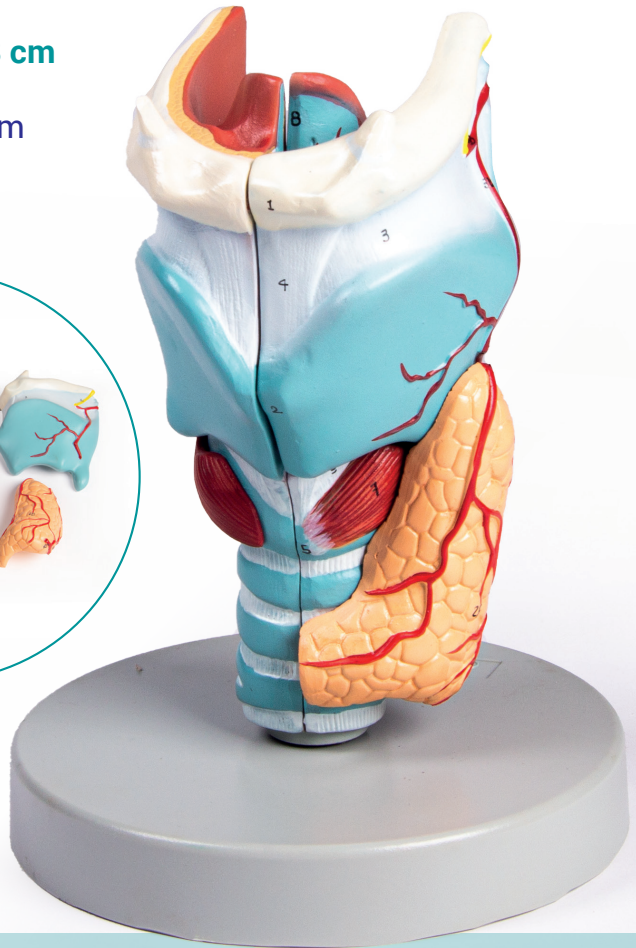
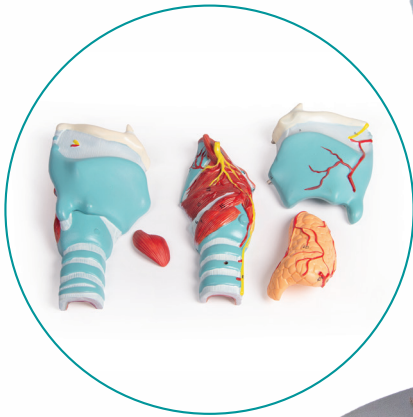

# Kehlkopfmodell

## Larynx model

G121 · 5 Teile  
Größe: 18 x 11 x 8 cm  
G121 · 5 parts  
Size: 18 x 11 x 8 cm



*Experts in medical education  
since 1950*



**ERLER ZIMMER**

Erler-Zimmer GmbH & Co. KG · Hauptstr. 27 · D-77886 Lauf  
Tel.: (+49) 7841 / 6003-0 · info@erler-zimmer.de · www.erler-zimmer.de

## English/ Latin/ Italian

### 1. Hyoid bone

- 1. Os hyoideum
- 1. Osso ioide

### 2. Thyroid cartilage

- 2. Cartilago thyroidea
- 2. Cartilagine tiroidea

### 3. Thyrohyoid membrane

- 3. Membrana thyrohyoidea
- 3. Membrana tiro-joidea

### 4. Medial thyrohyoid ligament

- 4. Lig. thyrohyoideum medianum
- 4. Legamento mediale tiroioideo

### 5. Cricoid cartilage

- 5. Cartilago cricoidea
- 5. Cartilagine cricoidea

### 6. Cricothyroid membrane

- 6. Membrana cricothyroidea
- 6. Membrana cricotiroidea

### 7. Cricothyroid muscle

- 7. M. cricothyroideus
- 7. Muscolo cricotiroideo

### 8. Epiglottic cartilage

- 8. Cartilago epiglottica
- 8. Cartilagine epiglottica

### 9. Arytenoid cartilage

- 9. Cartilago arytenoide
- 9. Cartilagine aritenoidea

### 10. Corniculate cartilage

- 10. Cartilago corniculata
- 10. Cartilagine corniculata

### 11. Cuneiform cartilage

- 11. Cartilago cuneiformis
- 11. Cartilagine cuneiforme

### 12. Triticeal cartilage

- 12. Cartilago triticea
- 12. Cartilagine triticea

### 13. Oblique arytenoid muscle

- 13. M. arytenoideus obliquus
- 13. Muscolo aritenoideo obliquo

### 14. Transverse arytenoid muscle

- 14. M. arytenoideus transversus
- 14. Muscolo aritenoideo trasverso

### 15. Lateral cricoarytenoid muscle

- 15. M. cricoarytenoideus lateralis
- 15. Muscolo cricoaritenoideo laterale

### 16. Posterior cricoarytenoid muscle

- 16. M. cricoarytenoideus posterior
- 16. Muscolo cricoaritenoideo posteriore

### 17. Thyroarytenoid muscle

- 17. M. thyroarytenoideus
- 17. Muscolo tiroaritenoideo

### 18. Oblique thyroarytenoid muscle

- 18. M. arytenoideus obliquus
- 18. Muscolo aritenoideo obliquo

### 19. Aryepiglottic muscle

- 19. M. aryepiglotticus
- 19. Muscolo ari-epiglottico

### 20. Aryepiglottic fold

- 20. Plica aryepiglottica
- 20. Plica ari-epiglottica

### 21. Stylopharyngeus muscle

- 21. M. stylopharyngeus
- 21. Muscolo stilofaringeo

### 22. Vestibular fold

- 22. Plica vestibularis
- 22. Piega vestibolare

### 23. Vocal fold

- 23. Plica vocalis
- 23. Piega vocale

### 24. Laryngeal vestibule

- 24. Vestibulum laryngis
- 24. Vestibolo della laringe

### 25. Ventricle of larynx

- 25. Ventriculus laryngis
- 25. Ventricolo della laringe

### 26. Infraglottic space

- 26. Cavitas infraglottica
- 26. Cavità infraglottica

### 27. Trachea

- 27. Trachea
- 27. Trachea

### 28. Thyroid gland

- 28. Glandula thyroidea
- 28. Tiroide

### 29. Parathyroid gland

- 29. Glandula parathyroidea
- 29. Paratiroide

### 30. Superior laryngeal nerve

- 30. N. laryngeus superior
- 30. Nervo laringeo superiore

### 31. Recurrent laryngeal nerve

- 31. N. laryngeus recurrens
- 31. Nervo ricorrente laringeo

### 32. Superior thyroid artery

- 32. A. thyroidea superior
- 32. Arteria tiroidea superiore

### 33. Superior laryngeal artery

- 33. A. laryngea superior
- 33. Arteria laringea superiore

### 34. Inferior thyroid artery

- 34. A. thyroidea inferior
- 34. Arteria tiroidea inferiore

### Abbreviations for the Latin terminology

- A. = Arteria
- Lig. = Ligamentum
- N. = Nervus
- M. = Musculus